UF College of Veterinary Medicine UNIVERSITY of FLORIDA

November 2014

Dr. Norman Ackerman served the University of Florida, College of Veterinary Medicine with distinction as Professor of Radiology from 1979 to 1994. A concerned teacher of veterinary students and residents of all disciplines, Dr. Ackerman also reached the veterinary scientific community through his writing. His numerous clinically pertinent publications are still today a vital part of the veterinary literature; therefore, it is appropriate this site perpetuates Dr. Ackerman's dedication to teaching. This site is presented in recognition of Dr. Norman Ackerman and his contributions to the field of veterinary diagnostic imaging.

Sponsorship of the display supports the Dr. Norman Ackerman Memorial Fund, dedicated to the teaching of diagnostic imaging residents at the University of Florida College of Veterinary Medicine.

- Boomer
- 8 year old MN Shih Tzu

Dr. Norman Ackerman Memorial Radiography Case Challenge

History and case presentation

- Boomer presents to your clinic with a history of tachypnea and labored breathing. The owner reports he was panting on his way to the groomer and he coughed a few times when at home. He was later found to be lethargic and inappetant.
- On physical examination, Boomer has pink mucous membranes, CRT <2 sec, RR 64 bpm, HR 120 bpm, 102.2 ° F, no murmur, normal synchronous pulse, tachypnea with increased lung sounds over the left cranial quadrant.

- Your plan includes radiographs of the thorax

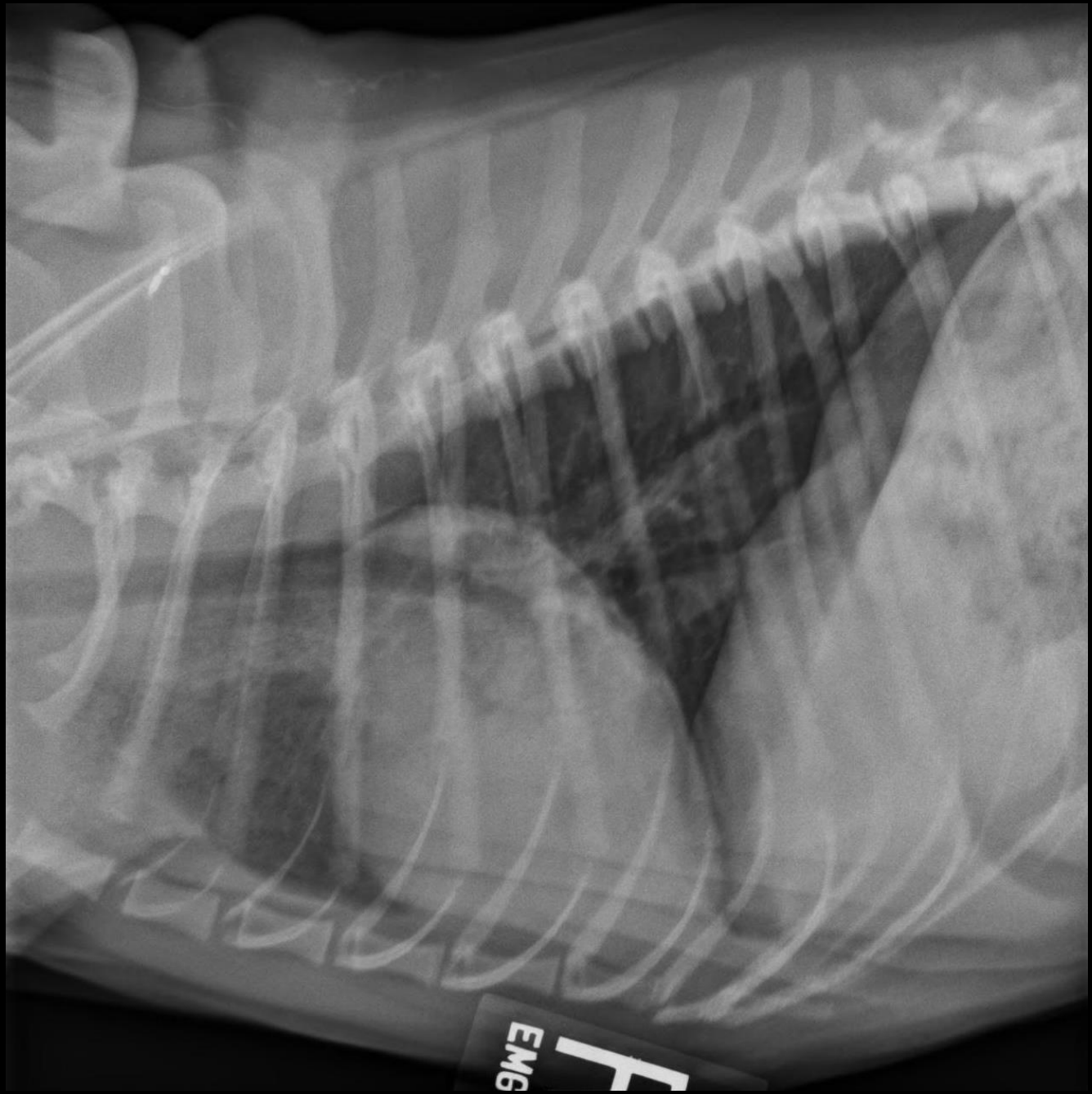
R
EMG

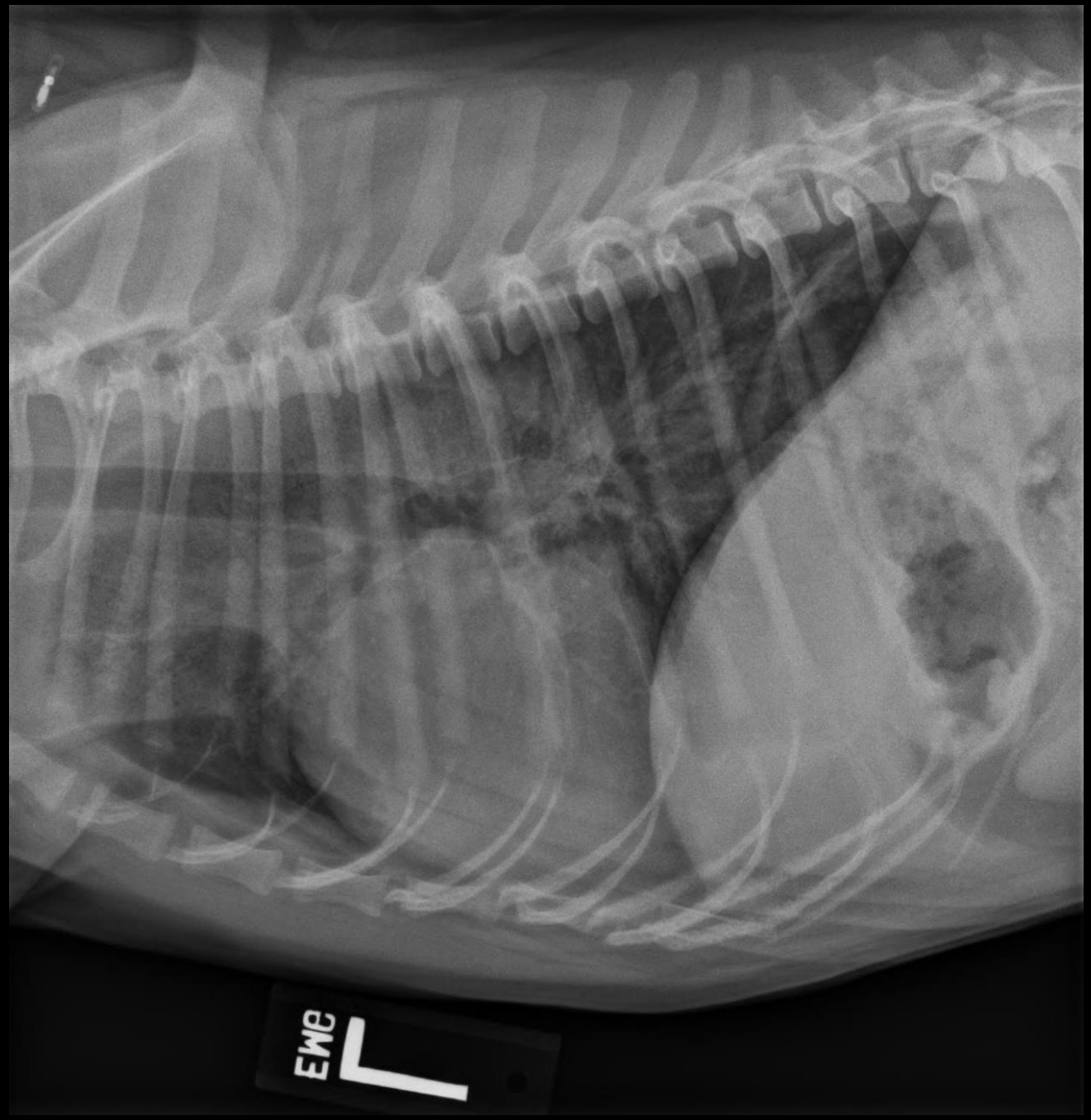
EWE
L

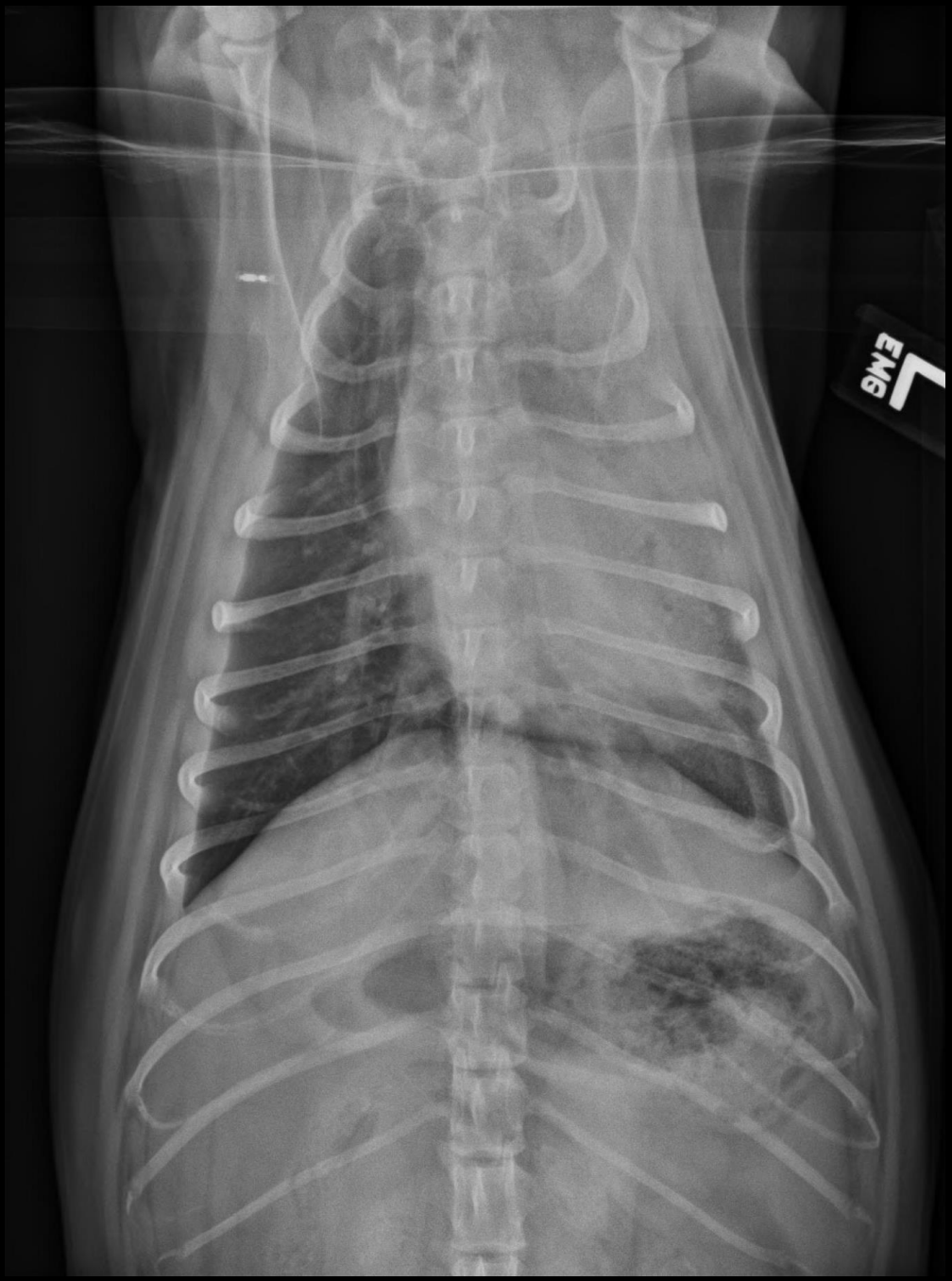
L
EMG


R
EWB

Findings

There is a severe diffuse increase in soft tissue opacity with associated small scattered gas bubbles throughout the cranial and caudal subsegments of the left cranial lung lobe.

In addition a mild increase in soft tissue opacity is noted within the left caudal lung lobe.

This increase in opacity results in an unstructured interstitial coalescing to alveolar pulmonary pattern, with evidence of air bronchograms, and border effacement with the cardiovascular structures.

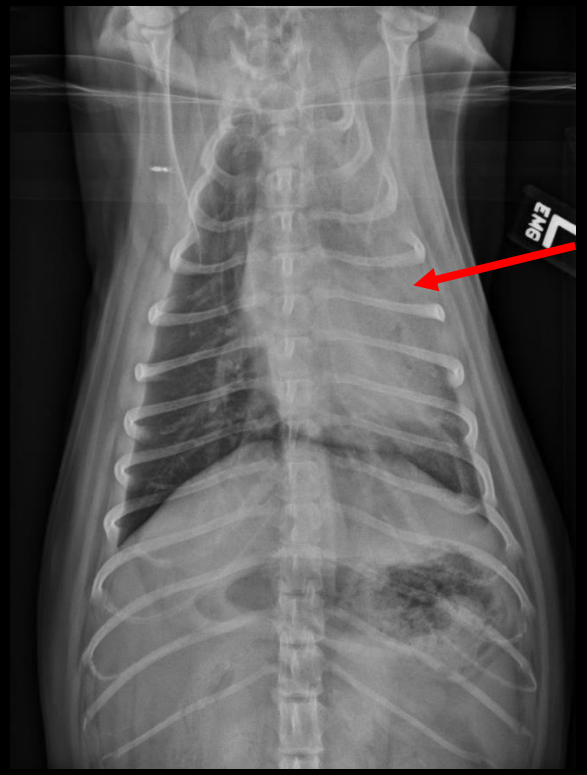

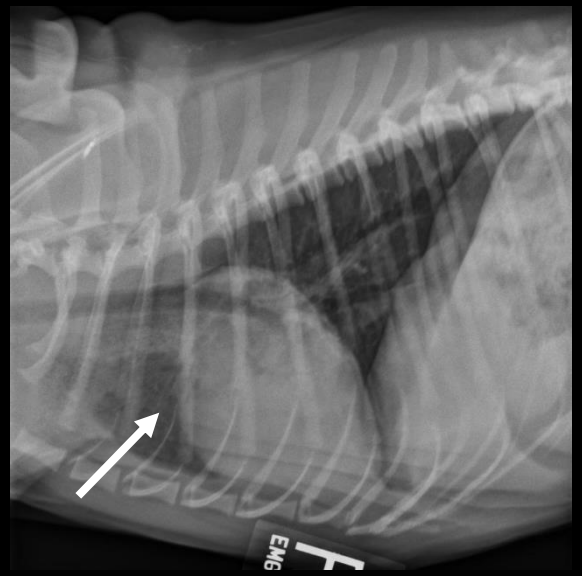

There is a curvilinear soft tissue opacity over the caudal and dorsal aspect of the heart base.

The left cranial lung lobe bronchus is not clearly identified.

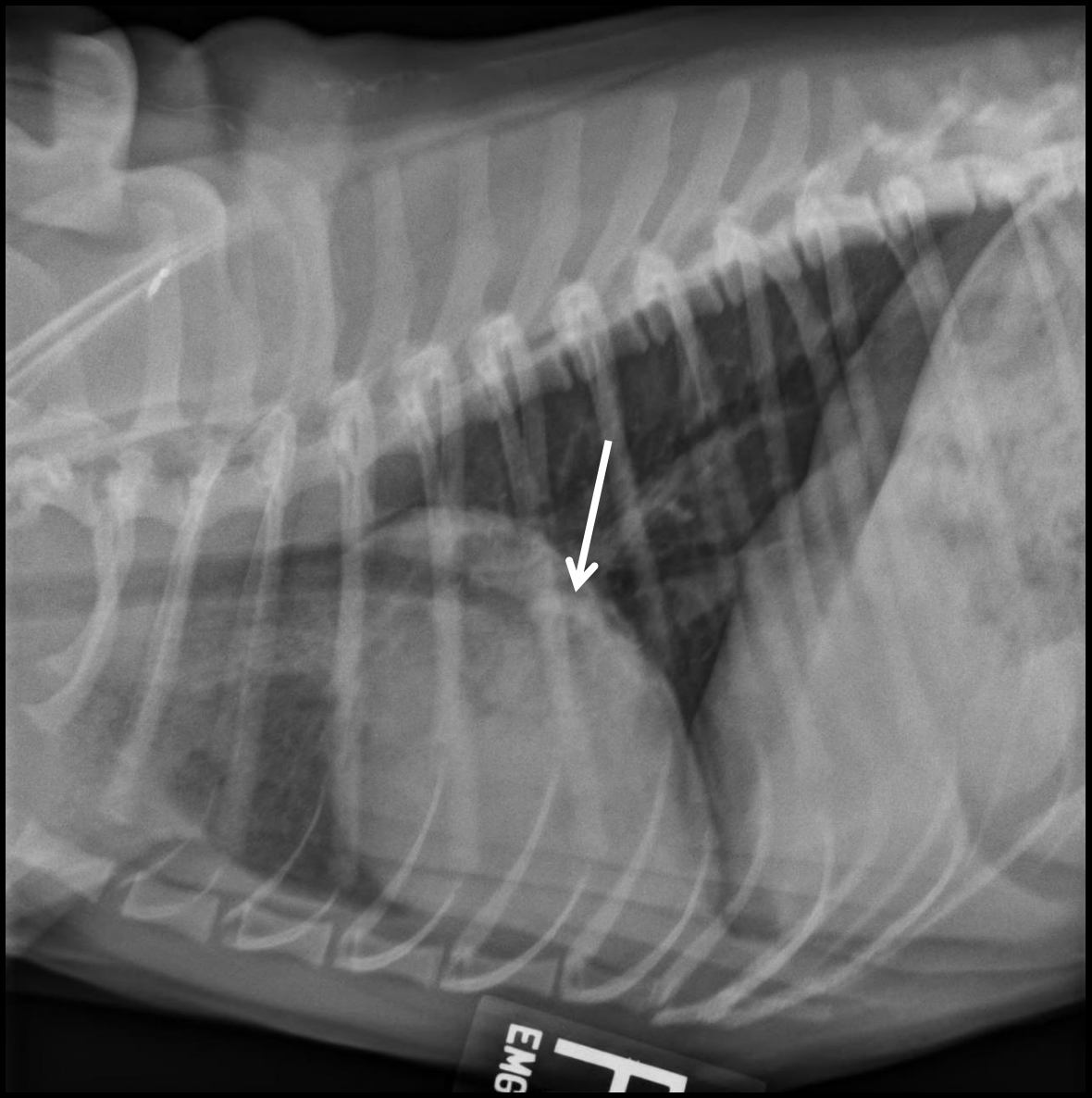

There is a leftward mediastinal shift of the cardiac silhouette.

Due to the increase in opacity in the region of the left cranial and left caudal lung lobes, it’s difficult to evaluate the cardiovascular structures in this region.

There is widening of the pleural fissure line between the left caudal and the accessory lung lobe that present rounded margins.

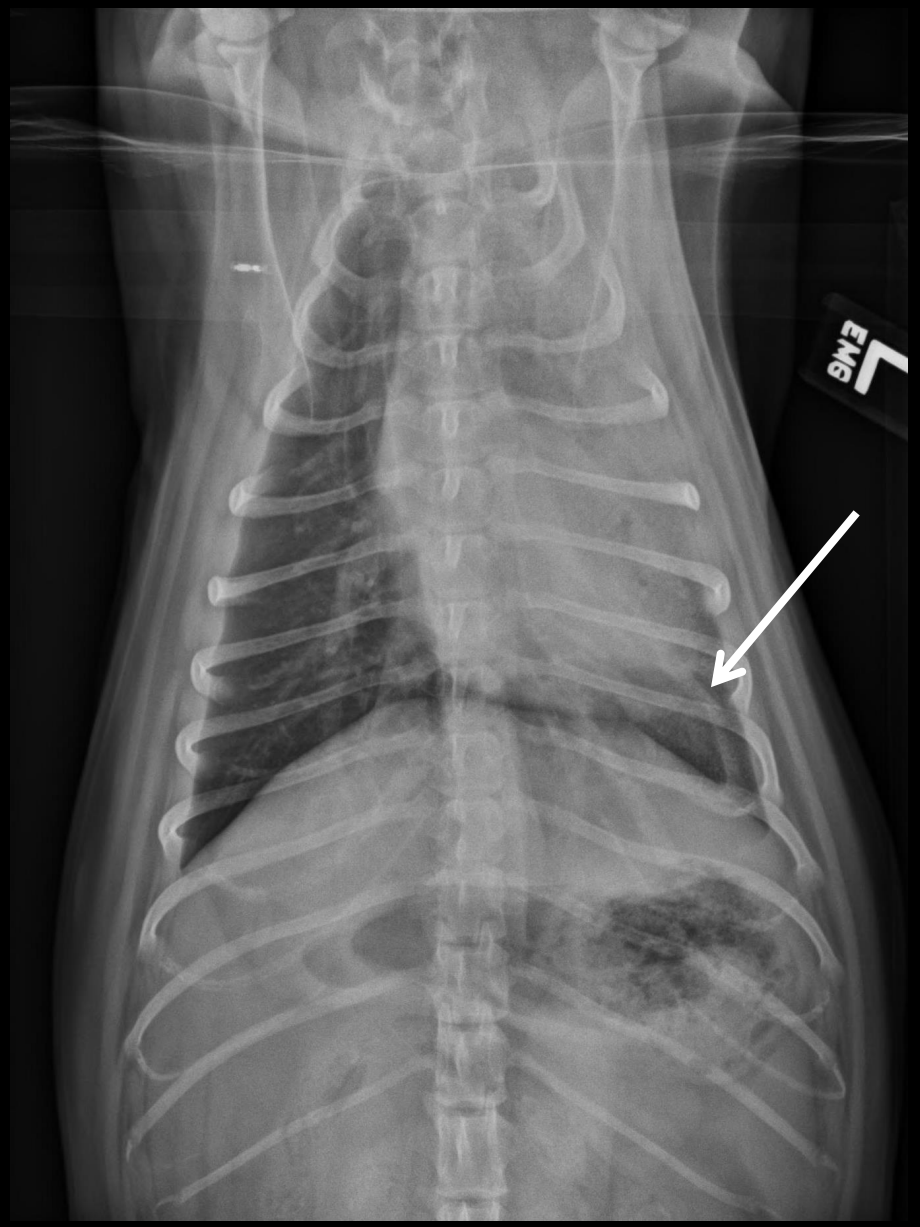

Conclusion

You have found a severe diffuse increase in soft tissue opacity with associated small scattered gas bubbles ("vescicular gas pattern") throughout the cranial and caudal subsegments of the left cranial lung lobe. In addition a mild increase in soft tissue opacity is noted within the left caudal lung lobe. This increase in opacity results in an unstructured interstitial coalescing to alveolar pulmonary pattern, with evidence of air bronchograms, and border effacement with the cardiovascular structures.

In addition you noted a curvilinear soft tissue opacity over the caudal and dorsal aspect of the heart base. You could not clearly identify, on the right lateral view, the left cranial lung lobe bronchus.

Furthermore, you recognized an ipsilateral mediastinal shift.

Also, you found rounding of the left caudal and accessory lung lobe margins with widening of the pleural fissure line between these lobes.

Your conclusions are: left-sided unstructured interstitial to alveolar pattern associated with lack of visualization of the left cranial lung lobar bronchus, ipsilateral mediastinal shift and mild volume unilateral (left-sided) pleural effusion. These radiographic abnormalities are consistent with a **left cranial lung lobe torsion (LLT)**.

Differential diagnosis

Other conditions that may lead to similar changes on chest radiographs are:

- pulmonary thromboembolism (PTE)
- pulmonary contusions
- neoplasia
- pneumonia
- atelectasis
- pleural hemorrhage
- coagulopathies
- diaphragmatic rupture
- pyothorax
- foreign body
- pulmonary abscesses

… your patient has a LLT!

Lung lobe torsion (LLT) is an axial rotation of a lung lobe and its pedicle, usually centered at or near the hilus. The pressure and wall resistance of the arteries supplying the lung permit afferent flow to remain, at least initially. Pulmonary venous and lymphatic congestion results, leading to parenchymal and alveolar edema, hemorrhage and necrosis.

Although ultrasonography and bronchoscopy can be useful, radiographs remain the primary imaging method.

The hallmark for the diagnosis of LLT is abnormal bronchial alignment indicating malposition of the affected lobe within the chest. Abnormally oriented or shaped air-filled bronchi, lobar atelectasis, lobar consolidation and lobar displacement have been described.

Increased lobar opacity with loss of visualization of the lobar vasculature and pleural effusion (PE), unilateral or bilateral, are generally present. If PE is present, thoracocentesis and drainage of the effusion should be performed. Radiography should then be repeated for the presence of lung lobe consolidation. Air bronchograms may be seen on radiographs in acute torsions, but this air slowly dissipates as the airways fill with infiltrate (edema fluid and blood).

Lung patterns with dispersed, small gas lucencies corresponding to vescicular emphysema have been described **(“vescicular gas pattern”**).

Mediastinal shift (ipsilateral or controlateral), curved and dorsally displaced trachea, axial rotation of the carina, pneumothorax (PTX) and pneumomediastinum have also been reported.

In addition…

Thoracic ultrasonography is a useful adjunctive tool for the diagnosis of LLT. US may allow the diagnosis to be established in the absence of conclusive radiographic signs.

A torsed lung lobe may appear hypoechoic at the periphery, filled with scattered reverberating foci consistent with gas in its central portion, rounded, in an abnormal position and surrounded by pleural effusion.

As the pulmonary parenchyma becomes consolidated, the torsed lung lobe may resemble normal liver tissue on ultrasonography, with the fluid-filled bronchi resembling hepatic vessels. This has been referred as ***hepatization*** of the torsed lung lobe.

Evaluation of the vascular supply to the lobe with color or power Doppler may be useful.

Positive-contrast bronchography (i.e. with viscous propyliodone) or **bronchoscopy** may allow visualization of bronchial occlusion within a torsed lung lobe. The first one has fallen out of favor due to safety concerns.

Computed tomography (with angiography) and **Magnetic Resonance Imaging** may be helpful if there are non specific findings on thoracic radiography.

Surgical resection of the affected lobe is the treatment of choice in small animals.

In patient with an identifiable underlying cause the prognosis depends on the underlying condition.

US in Boomer…

A small amount of anechoic fluid within the pleural space was noted.

In addition associated with the cranioventral aspect of the left cranial lung lobe, a large region of lung with a disrupted pleural margin was seen. This altered pleural region tapered to a region of the lung that had a homogeneous echotexture similar to that of a liver.

Blood flow was seen through the pulmonary vasculature on this portion of the lung, which is only seen in arteries.

An US-guided thoracocentisis was performed and hemorragic fluid was obtaind. Additionally FNAs of the hepatized lung were performed.

.

LLT

Lung lobe torsion.

Gicking JC, Aumann M. Compend Contin Educ Vet 2011; Apr 33(4):E4.

Lung lobe torsion (LLT) is a rare, life-threatening pulmonary disorder in small animals and in humans.

It occurs when the lung lobe rotates around the bronchus and vascular supply and remains in that position. Arterial inflow usually continues, leading to engorgement of the lobe and filling with the alveoli with blood. Pleural effusion, if not present may develop. Over time the torsed lung lobe becomes atelectic. Rarely multiple lung lobes can be affected.

A predisposition to LLT has been reported in large, deep-chested dogs. The Afghan hound is overrepresented, being 133 times more likely to develop lung lobe torsion than other breeds. Lung lobe torsion has been documented in a case series of pugs, as well as in Yorkshire Terriers, miniature Poodles, Pomeranian, Beagles and mixed-breed dogs. LLT has been reported in cats too, although the prevalence is much lower than in dogs.

Spontaneous LLT has been described in animals in which no predisposing factors that might change the spatial relationship among the lobes (pleural effusion, pneumothorax, previous thoracic surgery, thoracic trauma, diaphragmatic hernia and pathologic changes of the affected lobe/lobes), could be identified.

The most commonly affected lung lobes are the right middle and left cranial lobes (suggested tendency for left cranial LLT in small chondrodystrophic dogs), but torsion is reported in all lung lobes.

Historical findings are often nonspecific. Recent trauma, thoracic surgery or other concurrent or previous thoracic disease should raise the suspicion of a LLT. Clinical signs may include acute or chronic coughing,tachypnea, dyspnea, hemoptysis, and epistaxis. Systemic signs are typically non specific and include anorexia, lethargy, and fever.

Physical examination findings may include dyspnea, dull heart and lung sounds ventrally (PE), dull lung sounds dorsally (PTX), weakness, signs of shock, and cyanosis.

Radiographic evaluation of the thorax is considered the most important diagnostic test in the confirmation of LLT.

Surgical resection of the affected lobe is the treatment of choice in small animals.