UF College of Veterinary Medicine UNIVERSITY of FLORIDA

June 2014

Dr. Norman Ackerman served the University of Florida, College of Veterinary Medicine with distinction as Professor of Radiology from 1979 to 1994. A concerned teacher of veterinary students and residents of all disciplines, Dr. Ackerman also reached the veterinary scientific community through his writing. His numerous clinically pertinent publications are still today a vital part of the veterinary literature; therefore, it is appropriate this site perpetuates Dr Ackerman's dedication to teaching. This site is presented in recognition of Dr. Norman Ackerman and his contributions to the field of veterinary diagnostic imaging.

Sponsorship of the display supports the Dr. Norman Ackerman Memorial Fund, dedicated to the teaching of diagnostic imaging residents at the University of Florida College of Veterinary Medicine.

- Barlowe
- 8 year old MN Bernese Mountain Dog

Dr. Norman Ackerman Memorial Radiography Case Challenge

History and case presentation

- Barlowe presents to your clinic with a history of hematuria and pain following urination
- On physical examination, you detect pyrexia. His abdomen is very tense preventing easy palpation
- You order abdominal radiographs

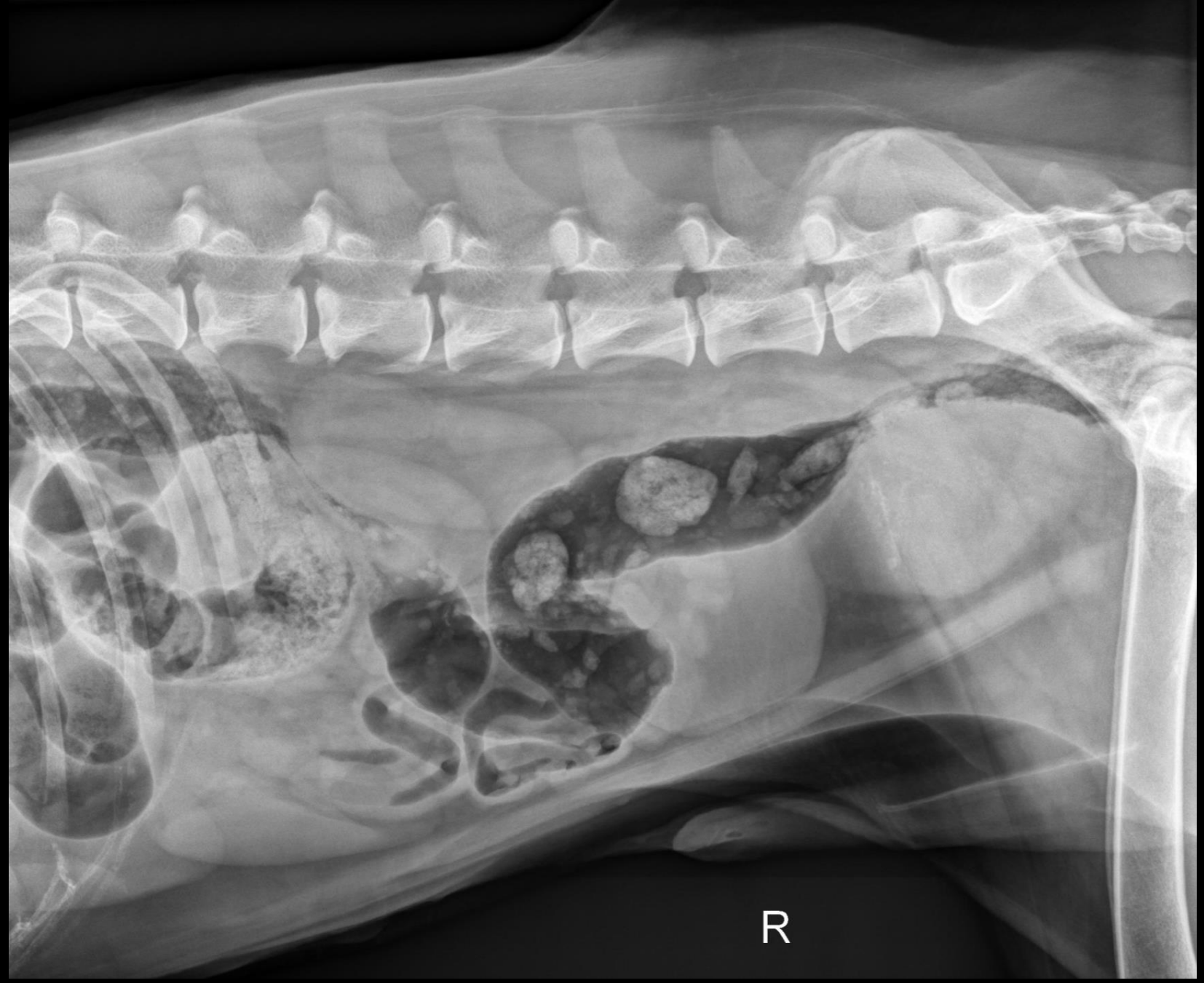
R


R

There is well-defined, oval, soft-tissue mass located ventral to the caudal lumbar and sacral vertebrae in the caudal abdomen. The mass is causing dorsal displacement of the descending colon. The position of this mass makes it most consistent with prostate.

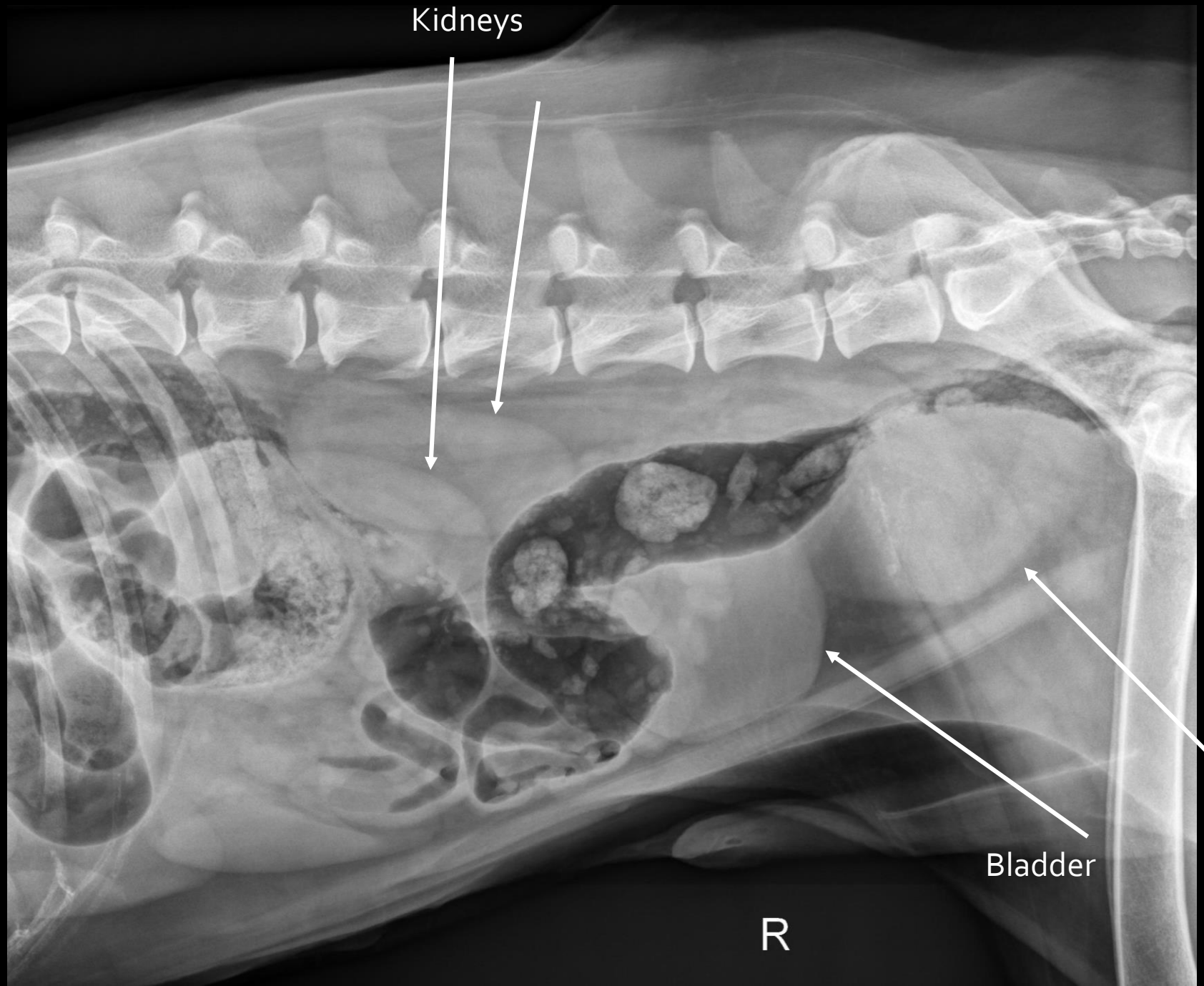
Kidneys
Enlarged prostate
Bladder
R

Differential diagnosis

The presence of mineralization within the prostate, along with the signalment (neutered, older male dog) makes prostatic neoplasia the most likely differential. Other differentials for prostatomegaly include benign prostatic hyperplasia, prostatic cysts and prostatitis.

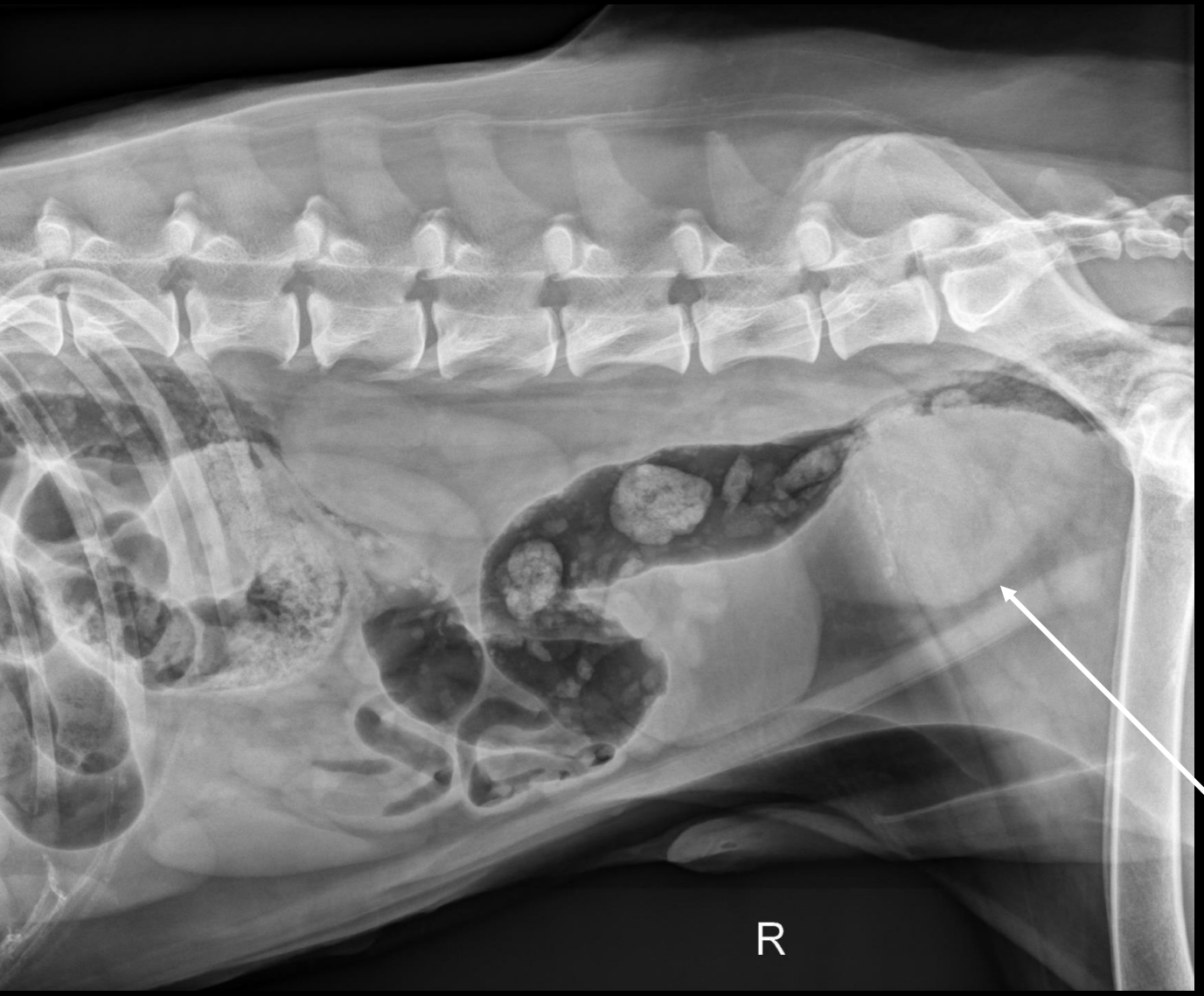

Enlarged prostate

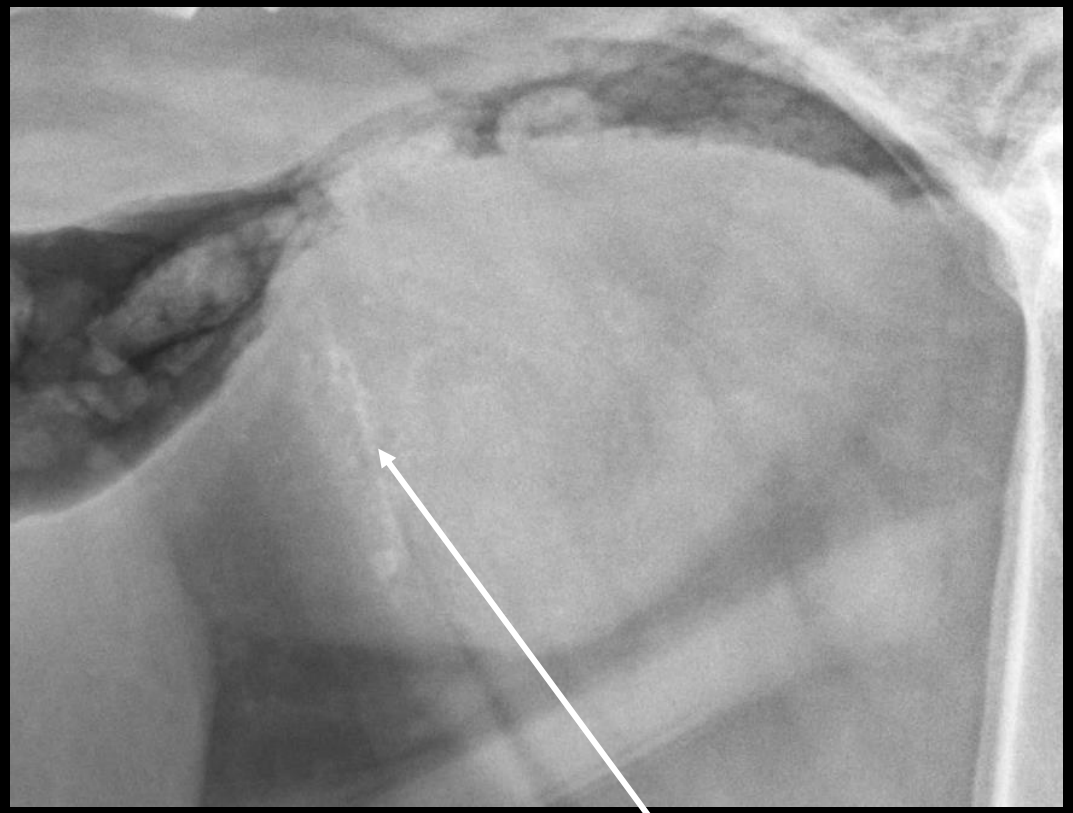

Linear mineralization

Conclusion

You have found a caudal abdominal soft-tissue opacity most consistent with an enlarged prostate, causing dorsal displacement of the colon. There are areas of linear mineralization within the mass, leading to a primary differential diagnosis of prostatic neoplasia.

Case Follow up

- You advise the owners that further diagnostics are needed to fully assess Barlowe's prognosis. You order further imaging of the prostate, cytology and staging.

Prostatic Neoplasia: Swinney (1998). *Prostatic neoplasia in five dogs*. Australian Veterinary Journal 76(10); 669-674.

- Major differentials for prostatic disease include benign prostatic hyperplasia, acute or chronic prostatitis, prostatic abscess, intra- or paraprostatic cysts and prostatic neoplasia.
- Prostatic neoplasms are usually malignant; prostatic adenocarcinoma is the most common. Other types include undifferentiated carcinoma, transitional cell carcinoma, leiomyosarcoma, squamous cell carcinoma and lymphoma. Metastatic neoplasia can metastasize to the prostate. Also, urethral TCC can locally invade the prostate.
- Prostatic neoplasms commonly metastasize to medial iliac lymph nodes, periprostatic tissue, bladder, pelvic lymph nodes, lungs, mesentery and rectum
- Prostatic neoplasia usually occurs in middle-aged or older, medium to large breed dogs.
- Prostatic neoplasia can occur in intact or neutered male dogs. Castration does not seem to be protective and in fact, prostatic neoplasms may be less differentiated and more likely to metastasize in castrated dogs.
- Dogs with prostatic neoplasia can present with a combination of urinary signs (hematuria, dysuria, incontinence), defecation abnormalities (tenesmus, constipation, dyschezia), systemic illness or locomotor abnormalities.
- On radiography, ill-defined prostate borders and increased opacity are suggestive of aggressive prostatic lesions. Mineralization can also occur in chronic prostatitis and prostatic calculi, however 80% of the time it occurs with neoplasia.
- Ultrasonography, CT, MRI, and cytology/histology can help with diagnosis and staging.